

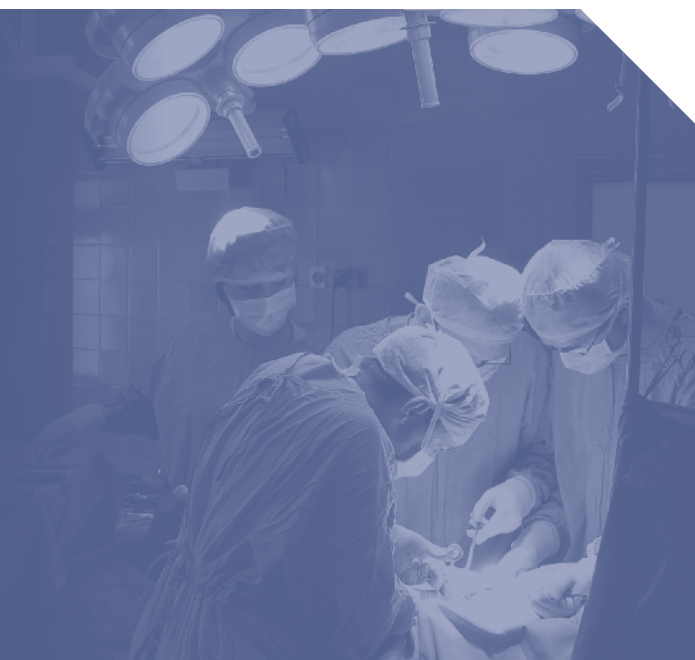Management of patients diagnosed with lumbar spinal stenosis and disc degeneration undergoing transforaminal lumbar interbody fusion using a novel ceramic implant with one year follow up.

Jim A Youssef, M.D.

Durango Orthopedic Associates/Spine Colorado, P.C.

Catherine A Patty, M.S.

Durango Orthopedic Associates/Spine Colorado, P.C.



Abstract

This case report focuses on the first clinical and radiographic outcomes of 2 patients with 1-year follow-up with a novel ceramic interbody implant which allows bony growth to occur onto the corresponding vertebral bodies as well as through the implant.

Historical reports of transforaminal lumbar interbody fusion (TLIF) reflect good clinical and radiographic outcomes. During the procedure, a structural support is placed within the middle or anterior aspect of the disc space accompanied by pedicle screw fixation.

Two patients underwent a TLIF procedure with posterior spinal fusion instrumentation and received the Valeo® TL (Valeo® TL Lumbar Interbody Fusion Device, Amedica® Corporation, Salt Lake City, UT) implant and were evaluated at 1-year for clinical and radiographic outcomes using CT scans and dynamic x-rays.

Length of hospital stay was 2 days in the hospital without complications. At 1-year, a CT scan and dynamic x-ray demonstrated solid interbody fusion and solid posterolateral fusion. Bone appeared to be well formed to the Valeo® TL implant as well as through and behind the implant in the interbody space; radiographic imaging was not distorted by the implant. These findings suggest that the Valeo® TL implant with its proprietary ceramic promotes bony growth on the implant; making the implant less likely to migrate as fusion occurs to the host vertebral bodies at the same rate as fusion occurs through the implant itself.

PEEK and carbon fiber implants may still migrate, despite concomitant posterior fixation, as there is no ability for bony ingrowth to the native vertebral bodies. These preliminary results suggest that the Valeo® TL implant may provide an attractive alternative for use in a TLIF procedure as compared to standard titanium, PEEK or carbon fiber grafts. The need for a larger prospective study to determine the efficacy of the use of Valeo® TL implant is warranted.

Introduction

Historically, reports of transforaminal lumbar interbody fusion (TLIF), first described by Blume² and popularized by Harms and Rolinger⁸, reflect good clinical and radiographic outcomes^{1,3,9,10,13}. In the TLIF procedure, a structural support (allograft bone or assorted cage designs) is placed within the middle or anterior aspect of the disc space via a posterolateral transforaminal route accompanied by pedicle screw fixation^{3,6,13}. Many interbody grafts have been created that not only focus on restoring disc height but also maintain lordosis through the vertebral segment, create distraction and restore the normal weight distribution within the anterior column¹³.

Aside from the mechanical properties, the graft must also have osteoconductive properties in order to promote fusion¹³. Although, most grafts do allow bony growth through the implant, this case report represents the first clinical experience with a novel ceramic graft that allows growth onto the implant as well as through the implant. The proprietary ceramic, composed of medical-grade silicon nitride with a special textured surface, allows such bony ingrowth to occur to the corresponding vertebral bodies.

Historically, imaging of these implants has been a challenge due to metallic scatter and distortion with sophisticated imaging such as MRI and CT. An abstract presented at the 8th Annual Spine Arthroplasty Society Global Symposium on Motion Preservation Technology in May 2008 compared the clinical visibility of cylindrical shaped specimens composed of cobalt chromium, PEEK, titanium and silicon nitride ceramic. As compared to the other commercially available specimens, the study concluded that silicon nitride ceramic implants may be easier to follow postoperatively from lack of distortion under magnetic resonance and lack of scattering under computed tomography (Anderson M, Bernero J, Brodke D: Medical imaging characteristics of silicon nitride ceramic: a new material for spinal arthroplasty implants. Abstract presented at the 8th Annual Spine Arthroplasty Society Global Symposium on Motion Preservation Technology, Miami, FL, May 2008).

This paper presents the clinical and radiographic outcomes of two patients that received the Valeo® TL (Valeo® TL Lumbar Interbody Fusion Device Amedica Corporation, Salt Lake City, UT) implant with one year follow up. This implant offers a dense, hydrophilic construct for load bearing, easy insertion and can be packed with autograft. As a non-oxide ceramic implant, it is strong, exhibits high fracture toughness, is hydrophilic and allows bony growth through the implant as well as onto the implant.

Case Report One

History and Physical Examination

A 47-year old woman reported back pain and weakness in her legs. The patient was diagnosed with lumbar spinal stenosis at L4-L5 with neurogenic claudication and axial low back pain at L4-L5, which failed nonoperative efforts. The patient was offered operative intervention in the form of a posterior decompressive laminectomy and posterior spinal fusion at L4-L5 using pedicle screw instrumentation and TLIF technique with application of interbody device, bone marrow aspirate, allograft bone and bone morphogenetic protein, as well as local bone.

Radiographic Imaging

A magnetic resonance imaging (MRI) scan of the lumbar spine was obtained. The MRI showed progressive disc herniation at L4-L5, moderate lateral recess stenosis, severe facet arthropathy, Modic changes within the vertebral bodies of L4 and L5 and a new central extrusion superimposed on a previously central disc protrusion (Figure 1).

Anterior-posterior (AP), lateral and flexion-extension x-ray views of the lumbar spine were also obtained. The x-rays showed increased angulation across the disc space but no evidence of any significant listhesis (Figure 2).

Preoperative Management

The patient was treated conservatively with physical therapy and oral medications. Due to the lack of improvement, treatment proceeded with diagnostic and therapeutic bilateral L5 transforaminal epidural injections. The injections were repeated in 2 months with no resolution of pain.

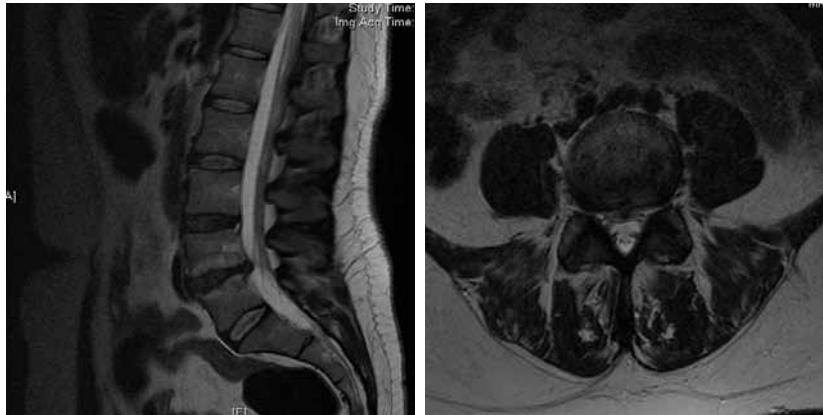

Figure 1 A

Figure 1 B

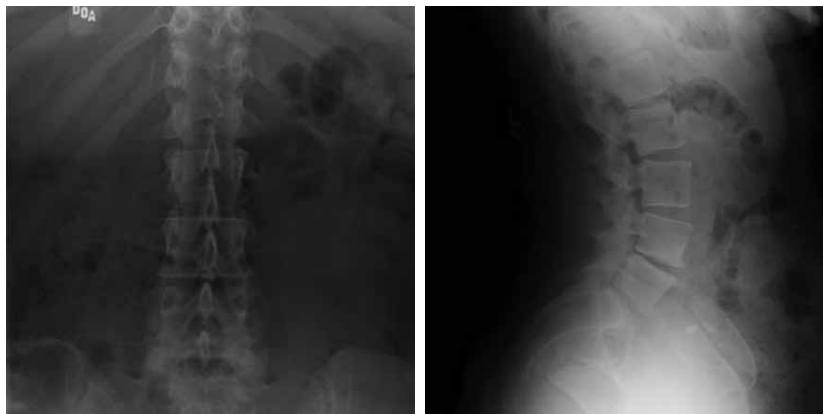


Figure 2 A

Figure 2 B

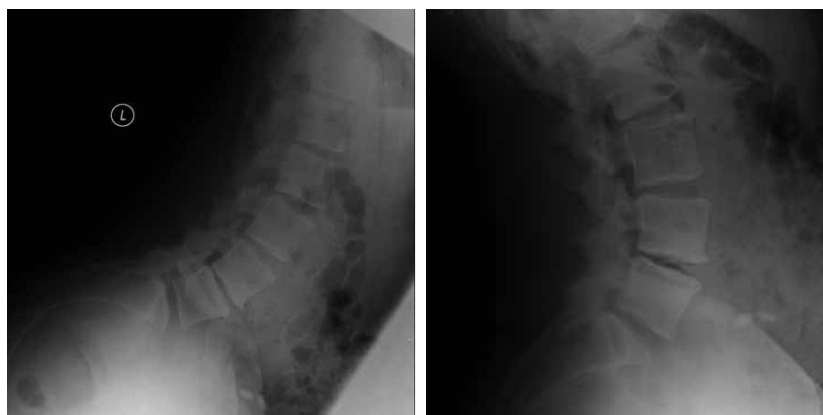

Figure 2 C

Figure 2 D

Operative Management

A standard decompression, including laminectomy, facetectomy, posterior spinal fusion (PSF) with instrumentation and TLIF was performed. Bone morphogenetic protein (Medtronic INFUSE® Bone Graft,

Minneapolis, MN) was placed in the implant. Local autograft harvested from lamina and spinous processes was placed posterior to the implant and in the disc space.

Postoperative Course

Length of stay was 2 days in the hospital without complications. Postoperative x-rays were obtained demonstrating excellent placement of the implants, excellent restoration of the disk space height and adequate placement of the pedicle screws (Figure 3).

At two-weeks postoperatively, all preoperative symptoms were resolved and the patient was walking over 2 miles a day. The patient was treated with a brace for 6-weeks postoperatively and started physical therapy shortly after being weaned off the brace. At one year follow-up, a CT scan and dynamic x-rays demonstrated solid interbody fusion and solid posterolateral fusion screws in expected position contained within the pedicles (Figure 3, 4). Bone appears to be well formed to the Valeo® TL implant as well as through and behind the implant in the interbody space.

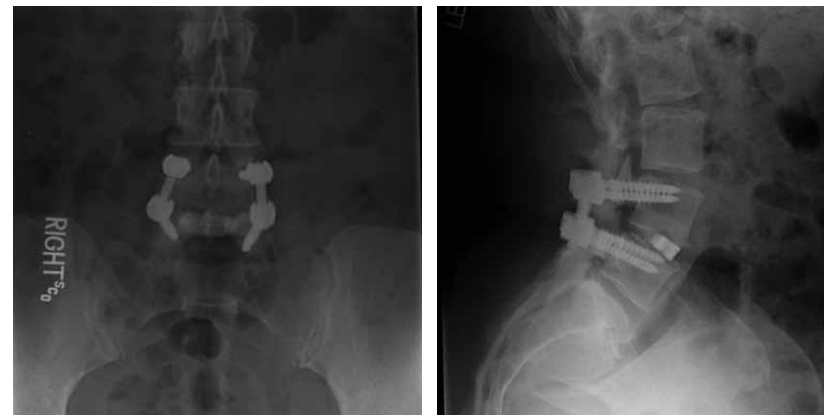

Figure 3 A

Figure 3 B

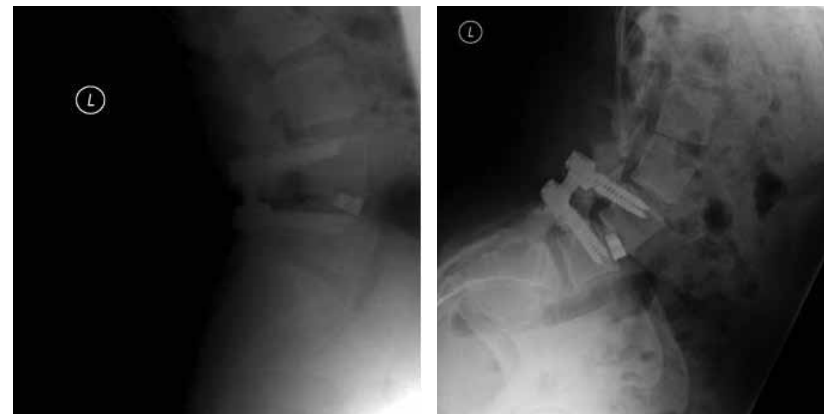

Figure 3 C

Figure 3 D

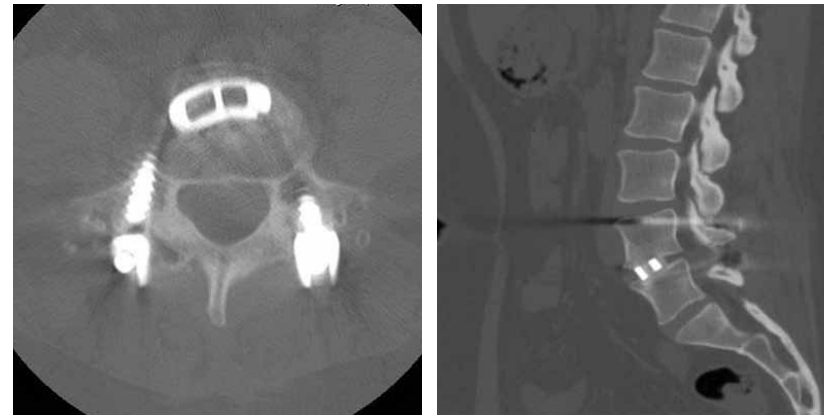

Figure 4 A

Figure 4 B

Case Report Two

History and Physical Examination

A 77 year old female with low back pain and bilateral leg pain, left greater than right. The patient was diagnosed with lumbar spinal stenosis L4-L5 and disc space collapse L4-L5, which failed nonoperative efforts. The patient was offered operative intervention in the form of posterior decompressive laminectomy and posterior spinal fusion at L4-L5 with TLIF and pedicle screw instrumentation at L4-L5.

Radiographic Imaging

An MRI scan showed 2 levels of stenosis, most severe on the right at L4-L5 with disc bulging, disc osteophyte complex, asymmetric disc collapse and severe stenosis at the L4-L5 level on the right. At L2-L3, the patient had some moderate central stenosis due to diffuse disc bulging (Figure 5).

Preoperative Management

The patient was treated conservatively with physical therapy and oral medications. Due to the lack of improvement, treatment proceeded with diagnostic and therapeutic bilateral L5 transforaminal epidural injection. The patient failed non-operative efforts and was offered operative intervention.

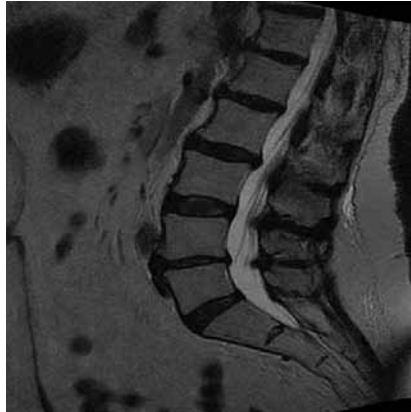


Figure 5 A

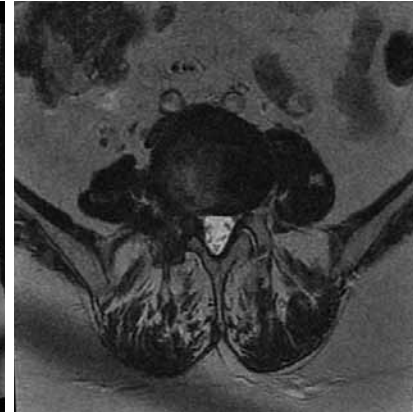


Figure 5 B

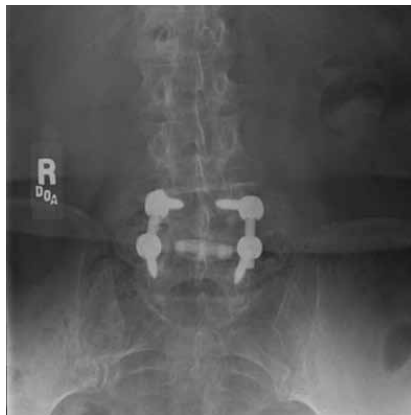

Figure 6 A

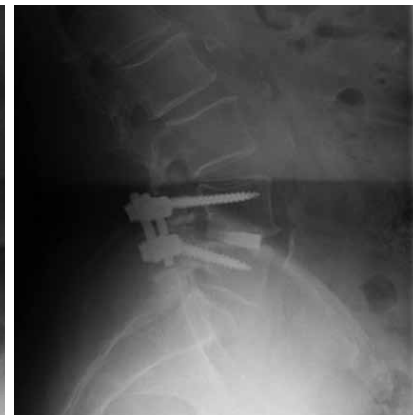

Figure 6 B

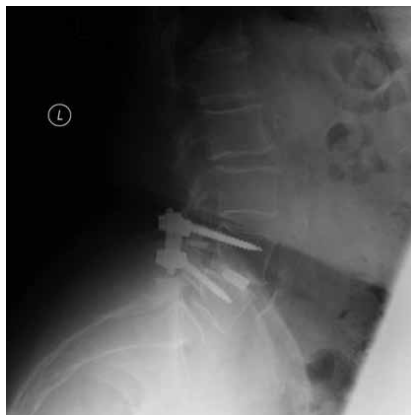

Figure 6 C

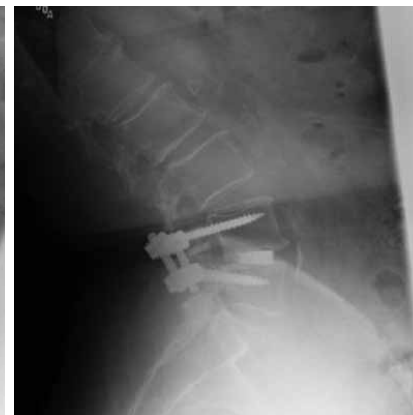

Figure 6 D

Operative Management

Similar to the first case report, the patient underwent a standard decompression, including laminectomy, facetectomy, posterior spinal fusion (PSF) with instrumentation and TLIF was performed. Bone morphogenetic protein (Medtronic INFUSE® Bone Graft, Minneapolis, MN) was placed in the ceramic implant. Local autograft harvested from lamina and spinous processes placed posterior to the implant and in the disc space.

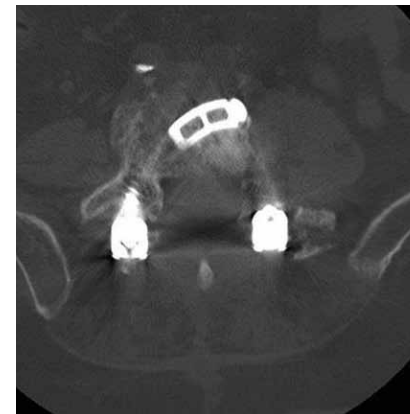


Figure 7 A

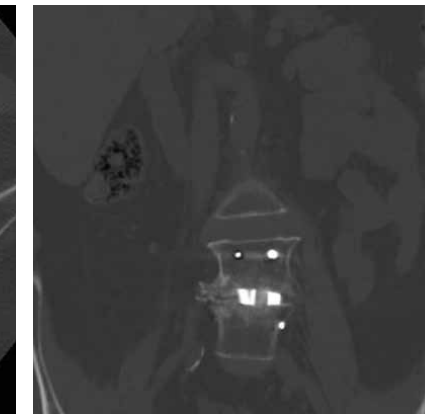


Figure 7 B

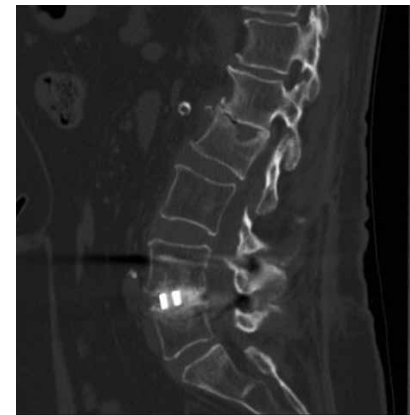


Figure 7 C

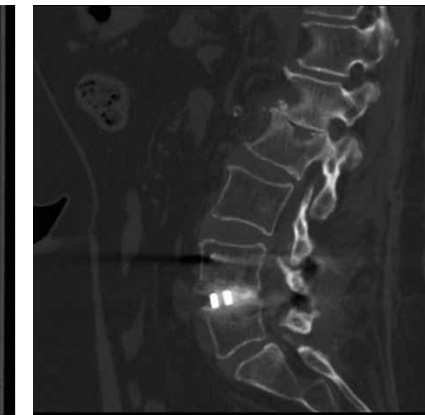


Figure 7 D

Postoperative Course

Length of stay was 2 days in the hospital without complications. At two-weeks postoperatively, the patient had some mild left leg pain, which decreased gradually. The patient was treated with a brace for 6-weeks postoperatively and started physical therapy shortly after being weaned off the brace.

At 14 months, dynamic x-rays and a CT scan both demonstrated an appropriately aligned L4-L5 fusion site with no hardware failure or other complication from the surgery. The interbody implant was correctly positioned at this level and showed good incorporation with osseous bridging through the center of the graft (Figure 6,7). Bone appears to be well formed to the Valeo® TL implant as well as through and behind the implant in the interbody space. There is no distortion of the imaging due to the implant.

Discussion

Transforaminal lumbar interbody fusion has emerged as a successful procedure for treating lumbar spinal stenosis and disc degeneration. Compared to posterior lumbar interbody fusion, historic literature presents findings that suggest successful outcomes after TLIF, low morbidity rates, decreased operative time, decreased operative blood loss, decreased incidence of dural tears and fusion rates as high as 92%^{9,11,13,16}. The TLIF technique can also provide immediate postoperative stability and correction of anatomical deformities^{3,17}. The TLIF procedure also leads to increased surface area for fusion since it spares the contralateral lamina, facet and pars³.

Considering the advantageous features of the TLIF technique, the design of synthetic interbody graft chosen for the procedure may potentially affect the clinical success of the procedure. Originally, titanium cages were placed in the interbody space during a TLIF procedure³. These cages lead to subsidence

through the vertebral body endplates, especially in osteoporotic patients³. Post-operative imaging was also challenging with the titanium interbody implants as the titanium results in significant image distortion making fusion determination challenging. With the problems associated with the use of metal cages, nonresorbable polymers, such as PEEK or carbon fiber reinforced PEEK (CFRP), were developed^{3,11}.

A large case series found that the rates of collapse, slippage and graft migration associated with the use of CFRP and PEEK cages were found to occur at rates of 3-10%^{3,4}.

Shortly after CFRP implants were popularized for use in TLIF procedures, porous ceramics were being developed for use in the TLIF procedure. These ceramics are known to be safe, allergy free and are associated with a high bone-bonding capacity. Most ceramics are attributed with osteointegration and osteoconductive properties. However, they do lack osteoinductive properties that are associated with allograft or autograft bone^{5,12}. The ceramic grafts are dependent on the remaining bone for their successful outcome¹². Literature has tried to focus on providing this capacity to ceramic implants by adding bone marrow cells⁷ or in addition to osteoinductive proteins¹⁴ to improve their osteoinductive capabilities.

The Valeo® TL implant is composed of micro-composite ceramic (MC²) with a surface that mimics cancellous structure. Valeo® implants incorporate a dense load-bearing component coupled with a surface texture, to promote bone attachment, more than traditional metal implants such as PEEK and titanium. Along with the increased bone growth properties, the Valeo® TL implant also has better compatibility with surgical and diagnostic imaging techniques.

The findings in this paper suggest that the Valeo® TL implant promotes bony growth onto the implant as well as through the implant. Due to the unique qualities, and better imaging compatibility, both patients demonstrated solid bony fusion on dynamic x-rays and CT scans at 1-year follow up. Our findings suggest that the Valeo® TL implant may provide an attractive alternative for use in a TLIF procedure as compared to standard titanium and CFRP implants.

Many studies have found that PEEK and CFRP implants may still migrate despite appropriate placement within the interbody space, as there is no ability for bony ingrowth to the native vertebral bodies^{1,15,18}. Aoki et al. presented a report of three patients with PEEK cage migration after a TLIF procedure. In this study, the authors suggested that surgeons use as much bone graft as possible, along with the PEEK cage, when packing the disc space; thereby, facilitating bony fusion prior to an event of cage migration. Ceramic implants, however, may not have this issue as there is bone adherence to the implant occurring at the same rate as the interbody fusion itself; therefore, the implant is less likely to migrate.

These preliminary results suggest that the Valeo® TL may provide an attractive alternative for use in a TLIF procedure as compared to standard titanium, PEEK or CFRP implants. The need for a larger prospective study to determine the efficacy of the use of Valeo® TL implant is warranted.

References

1. Aoki Y, Yamagata M, Nakajima F, Ikeda Y, Takahashi K: *Posterior migration of fusion cages in degenerative lumbar disease treated with transforaminal lumbar interbody fusion*. Spine 34(1):E54-E58, 2008.
2. Blume HG: *Unilateral posterior lumbar interbody fusion: simplified dowel technique*. Clin Orthop Relat Res 193:75-84, 1985.
3. Cole CD, McCall TD, Schmidt MH, Dailey AT: *Comparison of low back fusion techniques: transforaminal lumbar interbody fusion (TLIF) or posterior lumbar interbody fusion (PLIF) approaches*. Curr Rev Musculoskelet Med 2:118-126, 2009.
4. Collis JS: *Total disc replacement: a modified posterior lumbar interbody fusion. Report of 750 cases*. Clin Orthop Relat Res. 193:64-67, 1985.
5. Delécrin J, Takahashi S, Gouin F, Passuti N: *A synthetic porous ceramic as a bone graft substitute in the surgical management of scoliosis*. Spine 25(5):563-569, 2000.
6. Foley KT, Holly LT, Schwender JD: *Minimally invasive lumbar fusion*. Spine 28(15S):S26-S35, 2003.
7. Grundel RE, Chapman MW, Yee T, Moore DC: *Autogenic bone marrow and porous biphasic calcium phosphate ceramic for segmental bone defects in the canine ulna*. Clin Orthop 266:244-258, 1991.
8. Harms J, Rolinger H: *Die operative Behandlung der Spondylolisthese durch dorsal Aufrichtung und ventral Verblockung*. Z Orthop Ihre Grenzgeb 120:342-347, 1982.
9. Lauber S, Schulte TL, Liljenqvist U, Halm H, Hackenberg L: *Clinical and radiological 2-4-year results of transforaminal lumbar interbody fusion in degenerative and isthmic spondylolisthesis Grade 1 and 2*. Spine 31(15):1693-1698, 2006.
10. Lowe TG, Tahernia AD, O'Brien MF, Smith DAB: *Unilateral transforaminal posterior lumbar interbody fusion (TLIF): indications, technique and 2-year results*. J of Spinal Disord and Tech 15(1):31-38, 2002.
11. McAfee PC, DeVine JG, Chaput CD, Prybis BG, Fedder IL, Cunningham BW, et al: *The indications for interbody fusion cages in the treatment of spondylolisthesis: analysis of 120 cases*. Spine 30(6S):S60-S65, 2005.
12. Moore WR, Graves SE, Bain GI: *Synthetic bone grafts*. ANZ J Surg 71:354-361, 2001.
13. Mummaneni PV, Pan J, Haid RW, Rodts GE: *Contribution of recombinant human bone morphogenetic protein-2 to the rapid creation of interbody fusion when used in transforaminal lumbar interbody fusion: preliminary report*. J Neurosurg Spine 1:19-23, 2004.
14. Muschler GF, Huber B, Ullman T, Barth R, Easley K, Otis JO, et al: *Evaluation of bone-grafting materials in a new canine segmental spinal fusion model*. J Orthop Res 11:619-626, 1993.
15. Nguyen HV, Akbarnia BA, van Dam BE, Raiszadeh K, Bagheri R, Canale S, et al: *Anterior exposure of the spine for removal of lumbar interbody devices and implants*. Spine 31:2449-2453, 2006.
16. Salehi SA, Tawk R, Ganju A, LaMarca F, Liu JC, Ondra SL: *Transforaminal lumbar interbody fusion: surgical technique and results in 24 patients*. Neurosurgery 54:368-374, 2004.
17. Schwender JD, Holly LT, Rouben DP, Foley KT: *Minimally invasive transforaminal lumbar interbody fusion (TLIF): technical feasibility and initial results*. J Spinal Disord Tech 18(Supplement 1):S1-S6, 2005.
18. Taneichi H, Suda K, Kajino T, Matsumura A, Moridaira H, Kaneda K: *Unilateral transforaminal lumbar interbody fusion and bilateral anterior-column fixation with two Brantigan IIF cages per level: clinical outcomes during a minimum 2-year follow-up period*. J Neurosurg Spine 4:198-205, 2006.

Figure Legends

Figure 1.

Preoperative MRI of case 1. Sagittal (left) and axial (right) views showing progressive disc herniation at L4-L5, moderate lateral recess stenosis, severe facet arthropathy, Modic changes within the vertebral bodies of L4 and L5 and a new central extrusion superimposed on previously central disk protrusion.

Figure 2.

Preoperative dynamic radiographs of case 1. AP (A), lateral (B) and flexion-extension (C, D) x-ray views of the lumbar spine were also obtained. The x-rays showed increased angulation across the disc space but no evidence of any significant listhesis.

Figure 3.

Postoperative dynamic radiographs of case 1. AP (A), lateral (B) and flexion-extension (C, D) x-ray views of the lumbar spine at one year follow up, demonstrating excellent placement of the Valeo ceramic interbody implant, excellent restoration of the disk space height and excellent placement of the pedicle screws.

Figure 4.

Postoperative CT of case 1. At one year follow-up, axial (left) and sagittal (right) views demonstrated solid interbody fusion with no evidence of lucency between the implant and the vertebral bodies. Bone growth is seen through the implant, to the implant and behind the implant.

Figure 5.

Preoperative MRI of case 2. Sagittal (left) and axial (right) views showing 2 levels of stenosis, most severe on the right at L4-L5 with disc bulging, disc osteophyte complex, asymmetric disc collapse and severe stenosis at the L4-L5 level on the right. At L2-L3, the patient had some moderate central stenosis due to diffuse disc bulging.

Figure 6.

Postoperative dynamic radiographs of case 2. AP (A), lateral (B) and flexion-extension (C,D) x-ray views of the lumbar spine demonstrating excellent placement of the implants, excellent restoration of the disk space height and appropriate placement of the pedicle screws.

Figure 7.

Postoperative CT at one year of case 2. Axial (A), AP (B) and sagittal (C, D) show bone appearing to be well formed to the implant, as well as through the implant and behind the implant in the interbody space.

Jim A Youssef, M.D.

Phone: (970) 382-9500

jyoussef@spinecolorado.com

Catherine A Patty, M.S.

Phone: (970) 375-3696

kpatty@spinecolorado.com

Durango Orthopedic Associates/Spine Colorado, P.C.

1 Mercado Street, Suite 200

Durango, CO 81301

Fax: (970) 259-6045

Disclosure

The following author acknowledges a potential conflict of interest: JAY, royalties, stock options from Amica® Corporation, Salt Lake City, UT.

